

AGE 40
 DOUBLE PUNCH

MALE SEX

DIED DURING OR AFTER ANAES. NONE
 OPERATIVE OR OTHER ANAESTHETIC RESPONSIBLE MALAISE VOMITING OTHER

MECHANICAL RESPIRATOR MANUAL RESPIRATOR OR C.R. T. PIECE SELF-OPEN ABSORPTION ENDOTRACHEAL ENDOBRONCHIAL ANAES. OR BLOCKER NONE OTHER ETHER C₂H₆ T.C.E. HALOTHANE N₂

NON-DEPOLARIZER DEPOLARIZER NONE OTHER

HYPOTENSIVE PETHIDINE OR OPIATE BARBITURATE

RECORD OF SPECIAL INTEREST

DATE 5.6.72 No. 4420 141 **ANAESTHETIC RECORD** ANAESTHETIST TeB

NAME HAMED bin SHID AGE 25
 HOSP. & WARD RST - Int. WT. 60kg
 B.P. 120/- T.P.R. — 100— Hb. —

SURGEON Johnston./Cetti.
 OPERATION PERFORMED Laparotomy

PREOPERATIVE FINDINGS :-
 Wounds @ leg x 2 3
 Marked wounds @ groin / @ chest / @ arm
 Rigid abdo.
 X-ray shows some blood in chest.
 @ pleural rub. diminished most.
 Metal fragment ~~wound~~ in stomach.

POSTOPERATIVE PROGRESS :- Good.
 Fair amount of oozing from wound in thigh.

Fragment passed through @ chest, taking piece of rib and piercing fundus of stomach.
 Second fragment punctured saphenous vein.

PREMEDICATION :-

FINAL RESULT :-

3 HRS. ANAES.
 SPINE & BACK INTRA-CRANIAL

SITE OF OPERATION
 MOUTH, NOSE & THROAT THYROID OTHER HEAD & NECK HEART & GT. VESSELS PULMONARY OTHER INTRA-THORACIC CHEST WALL LUMBAR UPPER ABDOMINAL LOWER ABDOMINAL INGUINAL PERINEAL EXTREMITIES

NOOP. DIAG. EXP. THERAP. :
 CARD. ARREST CONVULSION EXPLOSION OTHER CIRCULATORY UNCOMPENSATED RESPIRATORY UNPROTECTED VOMITING OTHER

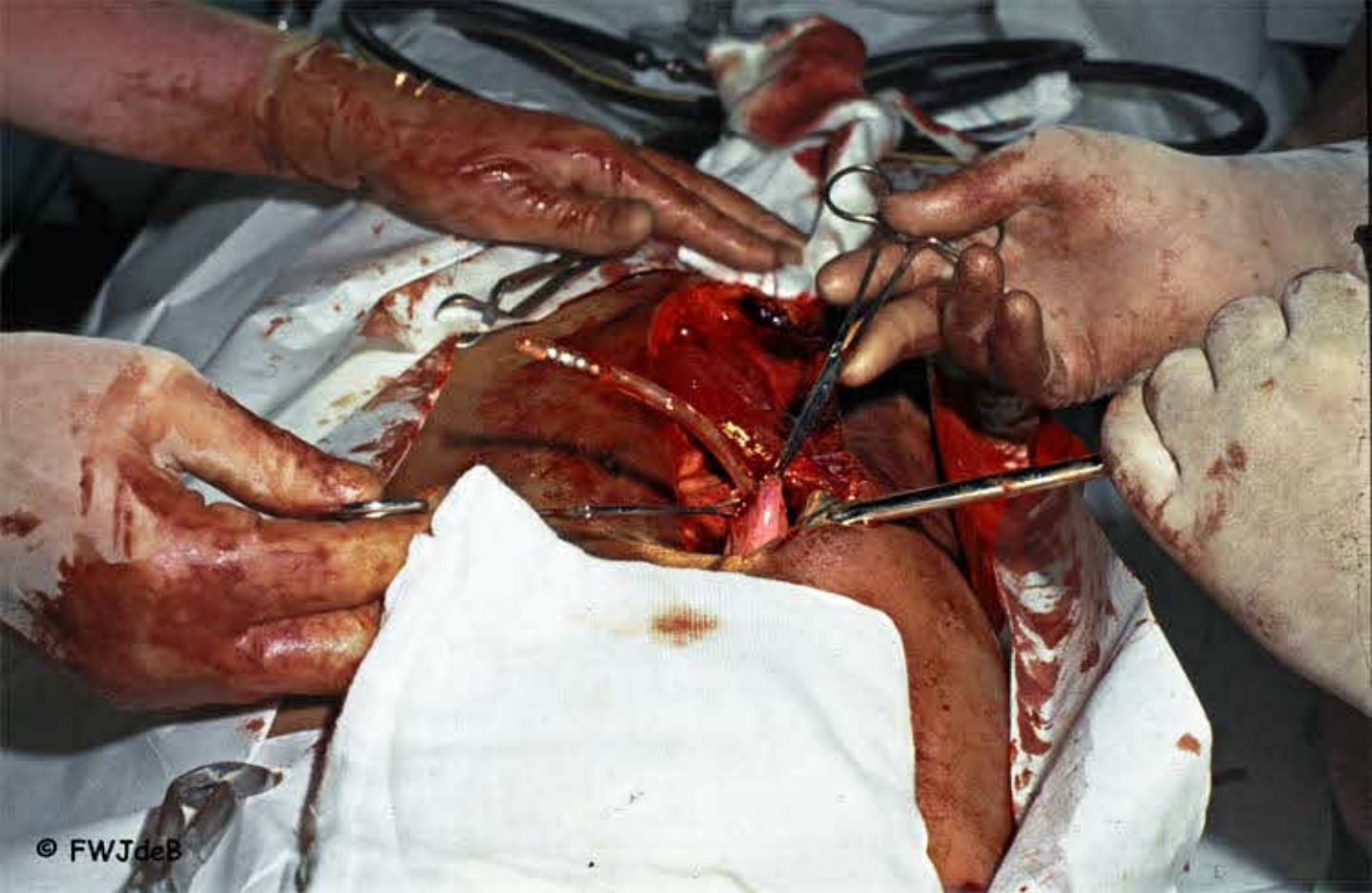
DISTURBANCES DURING ANAES. & THERAPY
 NONE BRADYCARDIA OTHER L.V. FIBRIL EXTRA-CORP. CIRCULATION HYPOTHERMIA OTHER

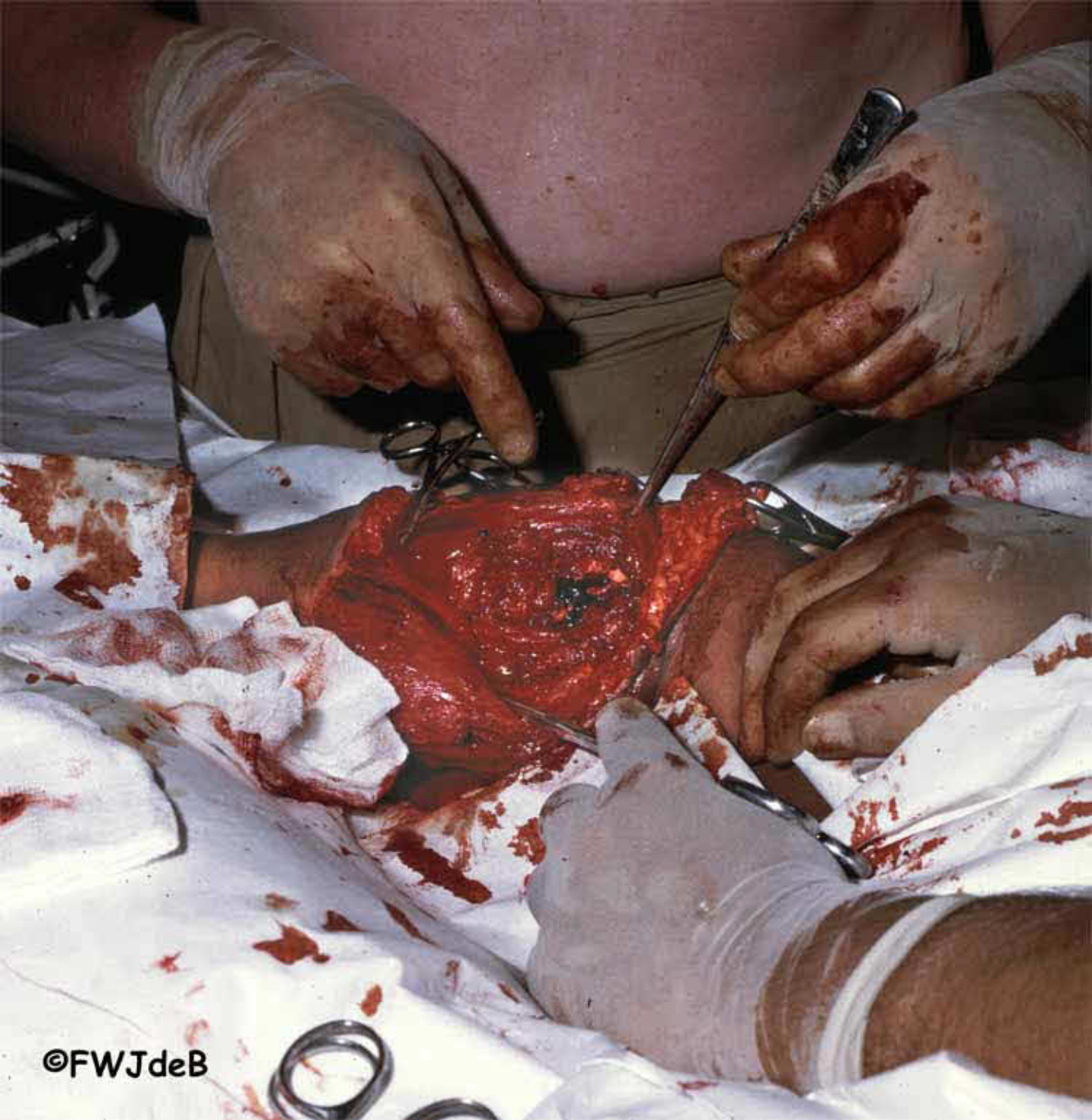
REGIONAL ANALGESIA
 SPINAL EPIDURAL OTHER NONE

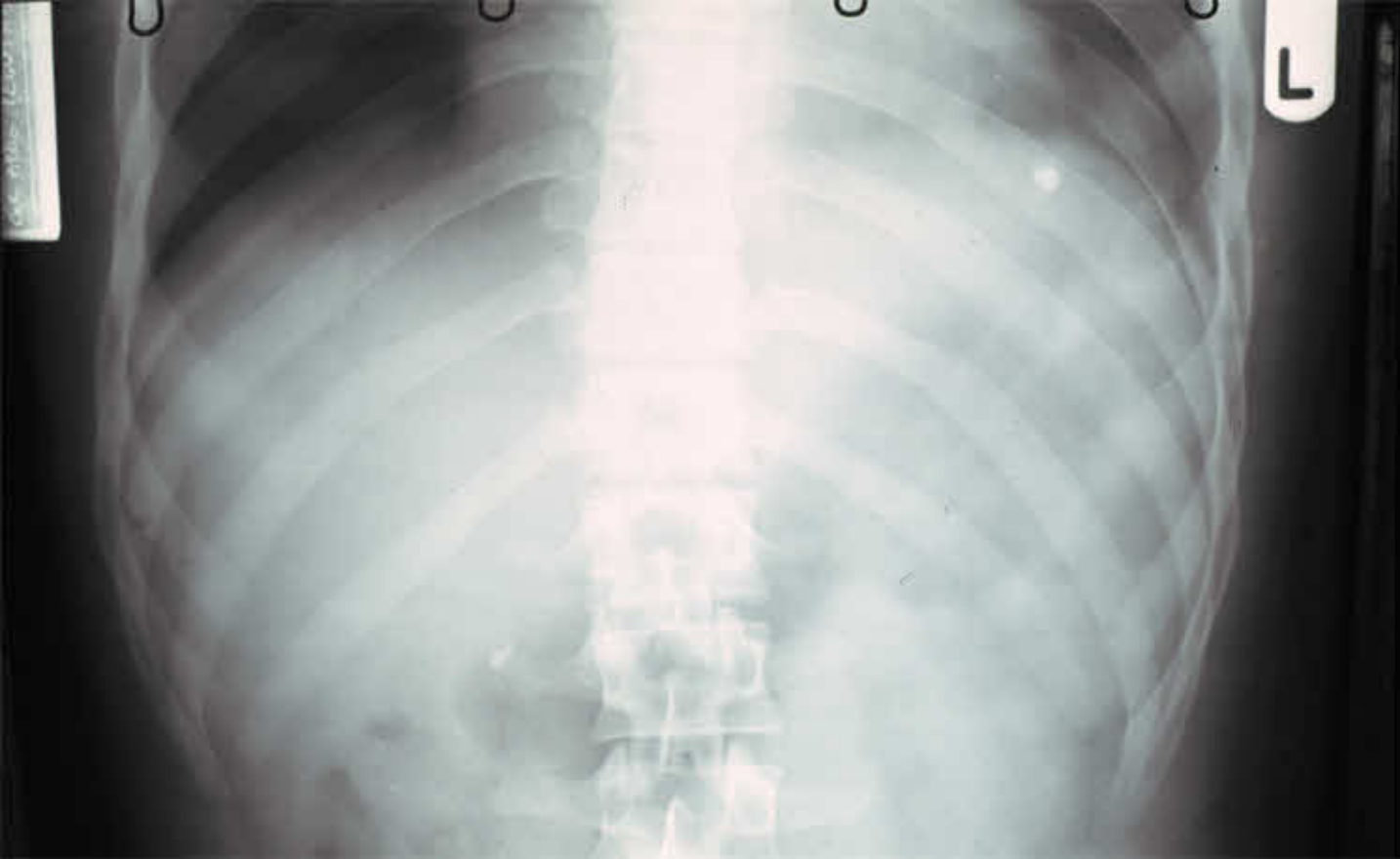PARAMOUNT REGD. TRADE MARK G.C. 8177 B. PRINTED IN ENGLAND.

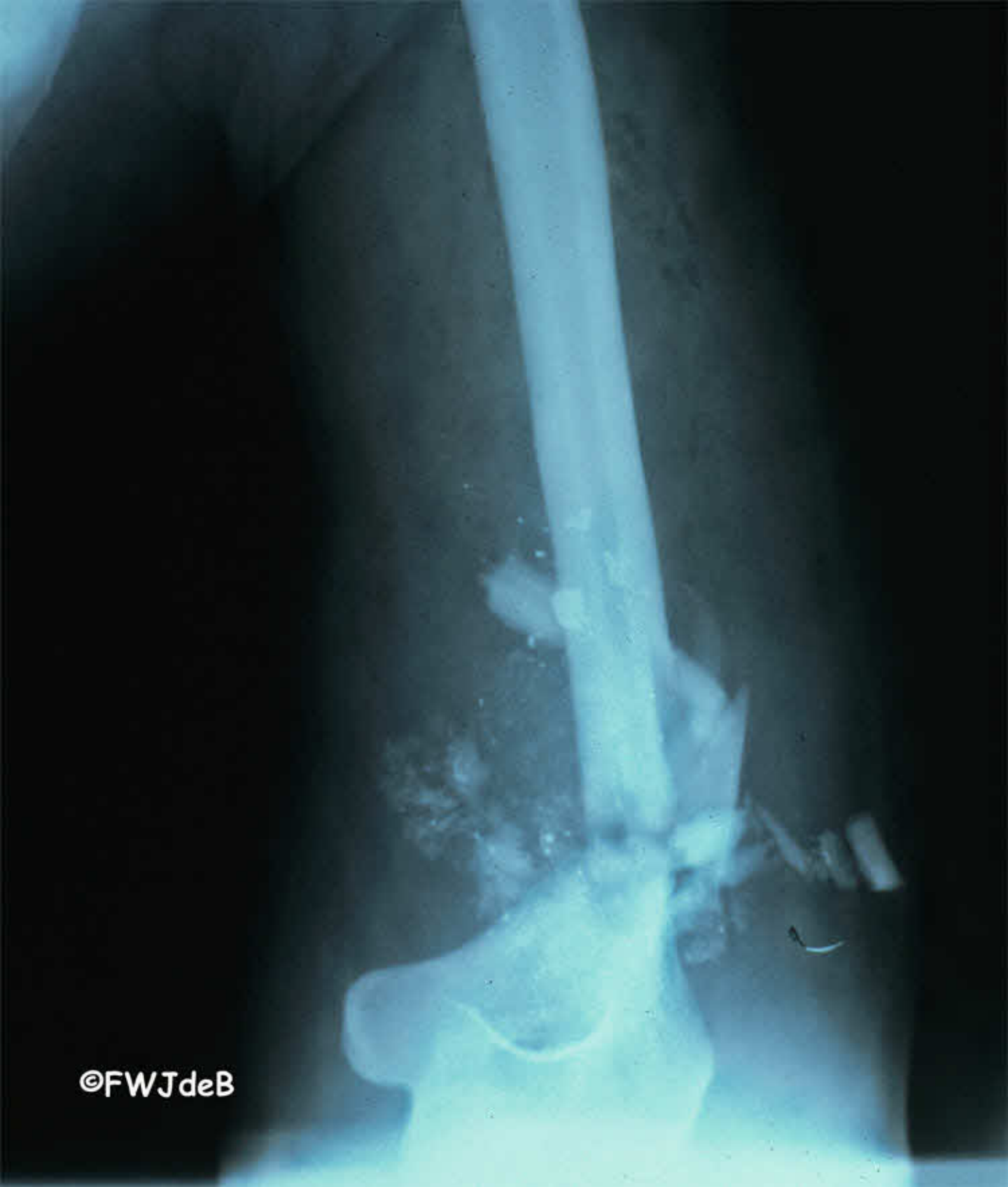INDIVIDUAL PRIVATE CODE

A B C D E F G H J K L M N O P Q R









©FWJdeB